


# **Ante partum Hemorrhage**

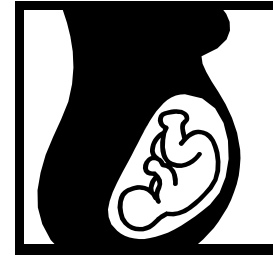**Shirin Hasanpour**

**Midwifery MSc.**

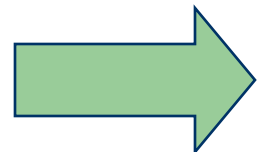
**Tabriz University of  
Medical Sciences**



# Background

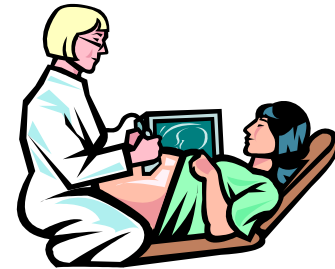

- Vaginal bleeding in late pregnancy is one of the leading causes of antepartum **hospitalization**, maternal **morbidity**, and **operative** intervention in the United States
- Antepartum hemorrhage complicates close to 4% of all pregnancies and is a **MEDICAL EMERGENCY!**
- Although much less common than in the past, obstetric hemorrhage is responsible for approximately **12%** of all maternal deaths in the U.S.A



- What are the most common causes of bleeding in the third trimester of pregnancy?

Think for a minute



# Differential Diagnosis of Third Trimester Bleeding

Placenta Previa

Placental Abruption

Uterine Rupture

Vasa Previa

Bloody Show

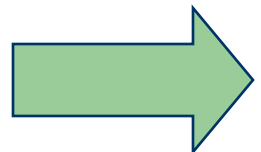
Coagulation Disorder

Vaginal Lesion/Injury

Cervical Lesion/Injury

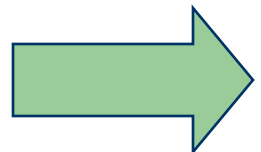
Neoplasia

\*Those highlighted in blue will be the focus of this Obstetrics Module



# Example Case:

- A 35 yo ,G3P2 , 33 weeks gestation presents to **painless vaginal bleeding**. Her pregnancy has been uneventful prior to this episode. She has no significant PMHx and takes no **medications** other than PNV. She does have a history of **tobacco** use, but denies illicit drug use. Her past obstetrical Hx is unavailable, but she is able to tell you that all of her **“labs”** have been normal and that her last pregnancy resulted in **C/S** due to failure to progress. Pt denies recent sexual **intercourse**. What would be the most likely cause of this presentation?



**With this presentation, what is the most likely diagnosis for this patient?**

- A) Placental Abruption
- B) Uterine Rupture
- C) Placenta Previa
- D) Vasa Previa

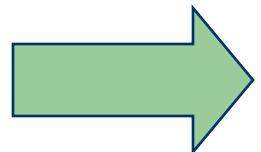
# Correct!

- The correct answer is C. Placental Previa
- Placenta previa is characterized by **painless bleeding** in the third trimester and is the **second most common cause of antepartum hemorrhage** after placental abruption. In this case, the patient complains of painless bleeding and has many risk factors consistent with this condition including **multiparity, Hx of C/S, and tobacco use**. Answers A, B, and D are less likely and will be discussed later in this module.



# Placenta Previa

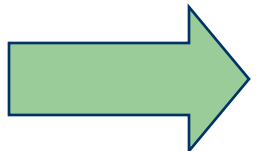
- **Defined** as the abnormal implantation of the placenta over the internal cervical os.
- **Bleeding** results from small disruptions in the placental attachment during normal development and thinning of the lower uterine segment





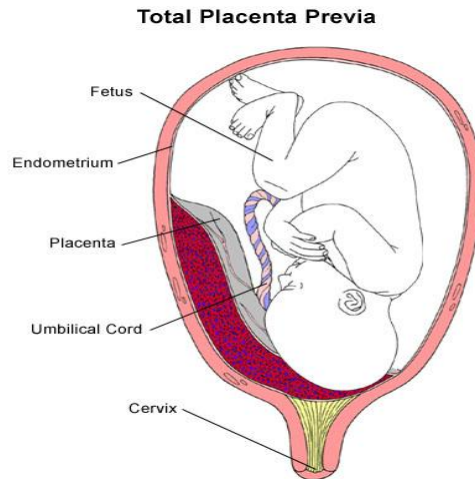
# Epidemiology

- Occurs in approximately **1 of every 300** pregnancies
- The diagnosis of placenta previa is common before the third trimester, but up to **95%** resolve before delivery

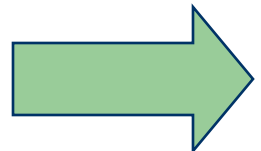
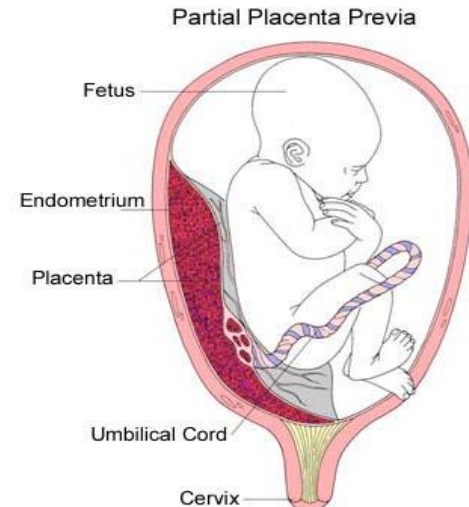


# Types of Placenta previa

- **Total Placental Previa**- occurs when the placenta completely covers the internal os. This is the most serious type due to the greatest risk of blood loss.

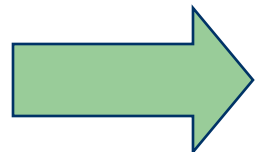


- **Partial Placental Previa**- occurs when the placenta covers a portion of the internal os



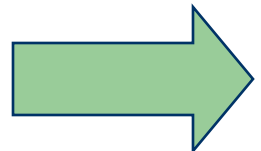
# Risk Factors for Placenta Previa

- Previous C/S
- Previous uterine instrumentation
- Multiparity
- Advanced maternal age
- Smoking
- Multiple gestation
- Prior placenta previa
- Uterine fibroids
- Unexplained elevation of MSAFP




# Morbidity and Mortality

- Placenta Previa is **rarely** a cause of life-threatening maternal hemorrhage unless instrumentation or digital exam is performed
- The most common morbidity with this problem is the necessity for operative delivery and the risks associated with **surgical intervention**
- Perinatal morbidity and mortality are primarily related to the complications of **prematurity**, because the hemorrhage is maternal.



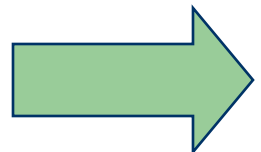
# Practical Question

- **Which physical examination findings and laboratory tests would you want to do in a patient suspected of having placenta previa?**



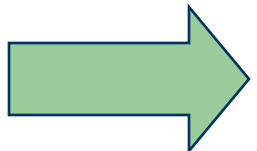
# Physical Findings and Laboratory Testing

- Maternal **abdomen** should be examined to assess: fundal height, fetal position, estimated fetal weight, and fetal heart tones
- Next a **STERIL SPEC** exam should be done- do **NOT** examine the cervix manually!
- Routine blood work for patients with significant vaginal bleeding should include maternal hematocrit or **CBC**, maternal **blood type and Rh** factor, and **coagulation** studies to rule out DIC



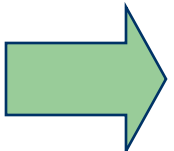
# High Yield Fact for Placental Previa

- The classic presentation of placental previa is **painless vaginal bleeding** and a **soft, nontender uterus**



## Example Case:

- A 28 yo Caucasian G2P1 ,31 weeks of pregnancy with sudden onset of **vaginal bleeding**. The patient had developed mild pregnancy-induced **HTN** 3 weeks earlier for which bed rest had been prescribed. She had been feeling well until this morning when a sharp **pain** developed in her belly. Quickly thereafter she noticed blood running down her leg. She immediately came to the hospital. The patient appears in considerable pain and has begun having irregular contractions every ten minutes. The **fetal heart tracing** is currently reassuring. An **U/S is unrevealing**. What is the most likely diagnosis?





**With this presentation, what is the most likely diagnosis for this patient?**

- A) Placental Abruption
- B) Uterine Rupture
- C) Placenta Previa
- D) Vasa Previa

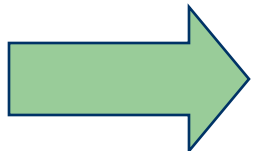
# Correct!

- The correct answer is A. Placental Abruption
  - Placental abruption is the **most common cause of late pregnancy bleeding** occurring in 1 of every 200 pregnancies. This condition is marked by **uterine bleeding (usually dark clots), uterine hyperactivity/hypertonicity, and fetal distress.**
  - Incorrect answers: Placenta previa, as already mentioned, is usually painless. We will discuss uterine rupture and vasa previa later in this module.

[Next](#) 

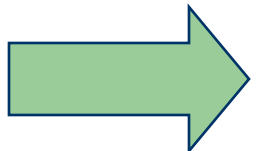
# Placental Abruption

- **Defined** as the premature separation of the placental from the uterine wall
- Occurs in **1 of every 200** pregnancies
- Perinatal mortality is reported as 119 per 1000 births (8.2 per 1000 among all other births)
- What are the risk factors for placental abruption?




# Risk Factors for Placental Abruption

- Hypertensive Disease of Pregnancy
- Smoking
- Substance abuse (i.e. cocaine)
- Polyhydramnios
- Hx of previous abruption
- Trauma



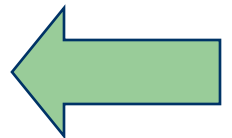
# Placental Abruption

- The **hallmark** symptom of placental abruption is pain which can vary from mild cramping to severe pain
- The **amount of external bleeding** may not accurately reflect the amount of blood loss. The blood present will most likely be dark, having been sequestered behind the placental membranes



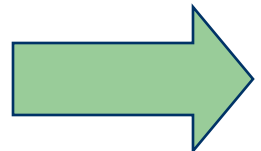
# Good Rule Of Thumb

- The presence of **pain between contractions** signals you to the possibility of **either placental abruption or chorioamnionitis**



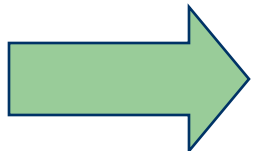
# Classification of Placental Abruption

- **Grade I**- mild vaginal bleeding; often due to retroplacental clot; an incidental finding after delivery
- **Grade II**- symptomatic patient with mild to moderate bleeding and a tender uterus; there is fetal distress, but the infant is alive
- **Grade III**- moderate to severe bleeding sufficiently severe to result in fetal demise
  - IIIa- abruption without coagulopathy (2/3)
  - IIIb- abruption with coagulopathy (1/3)



# Placental Abruption

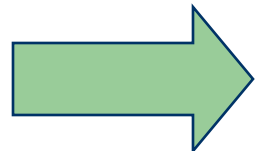
- Patient **history** should always include questions regarding trauma (including domestic violence), presence of pain and contractions, rupture of membranes, and assessment of risk factors
- The main principles of **clinical care** for abruption include: early delivery, adequate blood transfusion, adequate analgesia, monitoring of maternal condition, and assessment of fetal condition





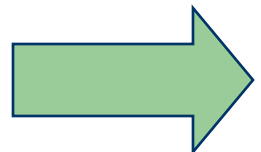
# High Yield Fact for Placental Abruption

- The classic presentation of placental abruption is **vaginal bleeding, painful contractions, and a firm, tender uterus**. Always consider the possibility of a **coagulopathy** in these patients.



# Example Case:

- A 32 yo G4P3, 40 weeks presents for labor **induction**. Pt had SVD with her first two pregnancies and had a **C/S** with her last pregnancy due to breech presentation. The pt had desired a **VBAC** with this pregnancy. After receiving high doses of pitocin, the patient develops severe **abdominal pain and heavy vaginal bleeding**. Fetal monitoring shows the development of **late decelerations** and bradycardia in the fetus. Abdominal exam reveals easily **palpable fetal parts**. The uterine contraction pattern remains normal. What is the most likely diagnosis?



**With this presentation, what is the most likely diagnosis for this patient?**

- A) Placental Abruption
- B) Uterine Rupture
- C) Placenta Previa
- D) Vasa Previa

# Correct!

- The correct answer is B) Uterine Rupture
  - Uterine rupture is characterized by **intense abdominal pain and bleeding** and **occurs at higher rates in pt's attempting a vaginal birth after caesarian section (VBAC)** and with uterine overstimulation during induction. Although other causes of antepartum hemorrhage should be considered, this diagnosis must be made promptly due to the risk to the patient and the necessity of surgical intervention.

[Next](#)

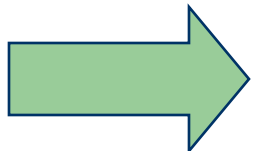
# Uterine rupture

- Reported in **0.03-0.08%** of all delivering women, but **0.3-1.7%** among women with a history of a uterine scar (from a C/S for example)
- **13%** of all uterine ruptures occur outside the hospital
- The most common maternal morbidity is **hemorrhage** and subsequent anemia, requiring transfusion
- **Fetal morbidity** is more common with extrusion and includes respiratory distress, hypoxia, acidemia, and neonatal death



# Uterine Rupture Presentation

- Classic presentation includes vaginal bleeding, pain, cessation of contractions, absence/deterioration of *fetal heart rate*, loss of *station*, easily palpable *fetal parts*, and profound maternal *tachycardia* and *hypotension*
- Patients with a prior uterine scar should be advised to come to the hospital for evaluation of new onset *contractions, abdominal pain, or vaginal bleeding*



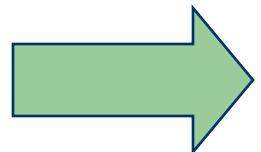
# Practical Question

- **Can you name any of the risk factors associated with uterine rupture?**



# Risk Factors for Uterine Rupture

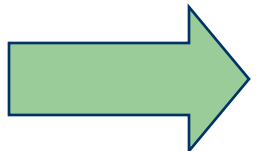
- Excessive uterine stimulation
- Hx of previous C/S
- Trauma
- Prior rupture
- Previous uterine surgery
- Multiparity
- Non-vertex fetal presentation
- Shoulder dystocia
- Forceps delivery





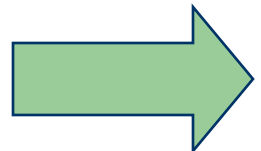
# Uterine Rupture Management

- In the case of sudden change in fetal baseline heart rate or the onset of severe decelerations, the provider should initiate **intrauterine resuscitation** with maternal position change, IVF hydration, O2 administration, and consideration of subcutaneous terbutaline
- If the measures are ineffective, emergent **laparotomy** is indicated



# High Yield Fact for Uterine Rupture

- The classic presentation for uterine rupture includes **intense abdominal pain, palpable fetal parts** in the maternal abdomen, and **a loss of station** of the baby's head from the birth canal



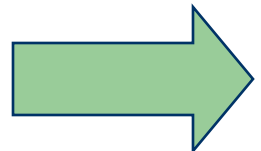
# Comparison of Presentation of Abruption v. Previa v. Rupture

## *abruption*      *previa*      *rupture*

<i>Abd pain</i>	<i>present</i>	<i>absent</i>	<i>variable</i>
<i>Vag bleeding</i>	<i>old</i>	<i>fresh</i>	<i>fresh</i>
<i>DIC</i>	<i>common</i>	<i>rare</i>	<i>rare</i>
<i>Acute</i>	<i>common</i>	<i>rare</i>	<i>common</i>
<i>fetal distress</i>			

# Example Case:

- A 34 yo G3P2 ,35 weeks gestation presents in active labor. She has a Hx of a previous precipitous delivery at 36 weeks' gestation. An U/S at 18 weeks gestation showed a **bilobed placenta**. Umbilical cord insertion was noted to be normal. The patient denies any discomfort other than during her contractions which are initially 3-5 minutes apart. Her labor progresses to 6 cm dilation, at which labor progression stalls. Consequently, an **AROM** is performed at which time bright red blood clots are noted. Within one minute, the **fetal heart rate** drops to 60-70 beats per minute. What is the most likely diagnosis?



**With this presentation, what is the most likely diagnosis?**

- A) Placental Abruption
- B) Uterine Rupture
- C) Placenta Previa
- D) Vasa Previa

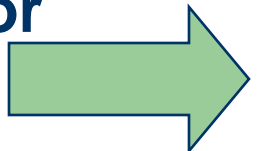
# Correct!

- The correct answer is D) Vasa Previa
  - Vasa Previa is a rare cause of antepartum hemorrhage that is characterized by the onset of bleeding at rupture of membranes. Placental abnormalities such as a bilobed placenta or a succenturiate lobe increase the risk for this condition. The other causes of antepartum hemorrhage are less likely with this presentation.



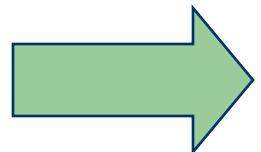
# Vasa Previa

- Rarely reported condition in which the fetal vessels from the placenta cross the entrance to the birth canal
- Reported incidence varies, but most resources note occurrence in **1:3000** pregnancies
- Associated with a high fetal mortality rate (**50-95%**) which can be attributed to rapid fetal exsanguinations resulting from the vessels tearing during labor



# What are the causes of aberrant vessels in vasa previa?

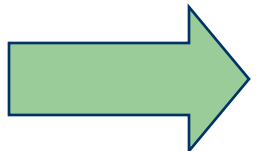
- There are three different causes typically noted for vasa previa:
  - 1) Bi-lobed placenta
  - 2) Velamentous insertion of the umbilical cord
  - 3) Succenturiate (Accessory) -lobed placenta



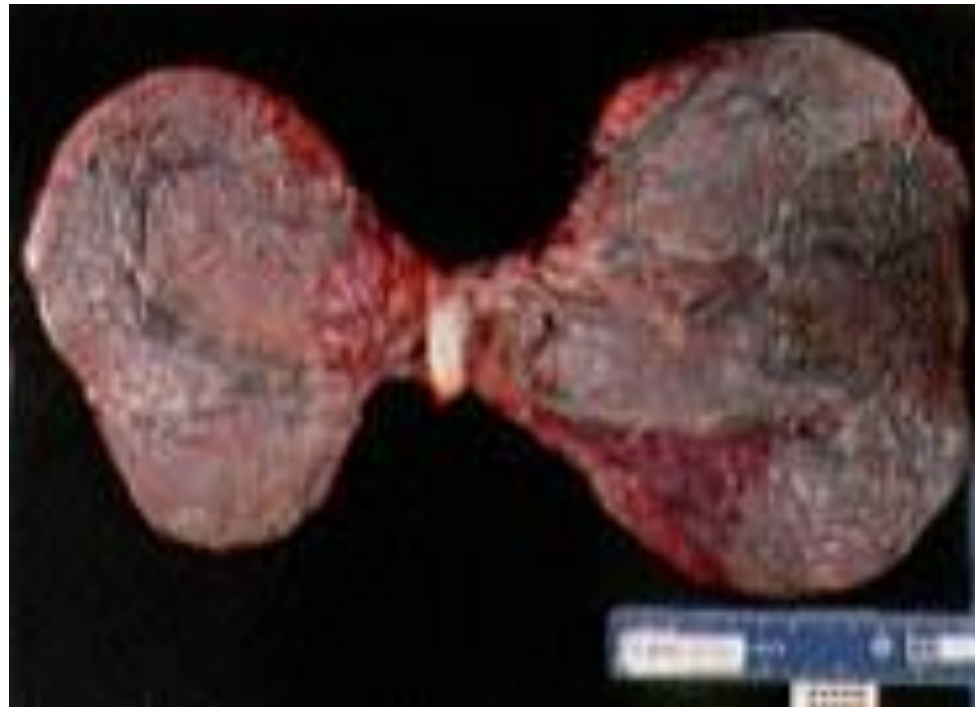

# Bi-lobed placenta

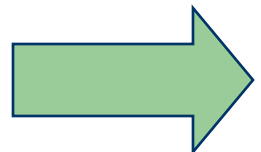
- The separation of the placenta into two distinct lobes of equal or near equal size
- Possibly a **genetic origin** due to the increased incidence in subsequent pregnancies
- **Umbilical cord** most often inserts into the membranes between the two lobes
- **Risk factors** include advanced maternal age, tobacco use in pregnancy, diabetes, and hyperemesis gravidarum



# Bi-lobed placenta

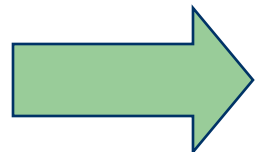


Shirin Hasanpour

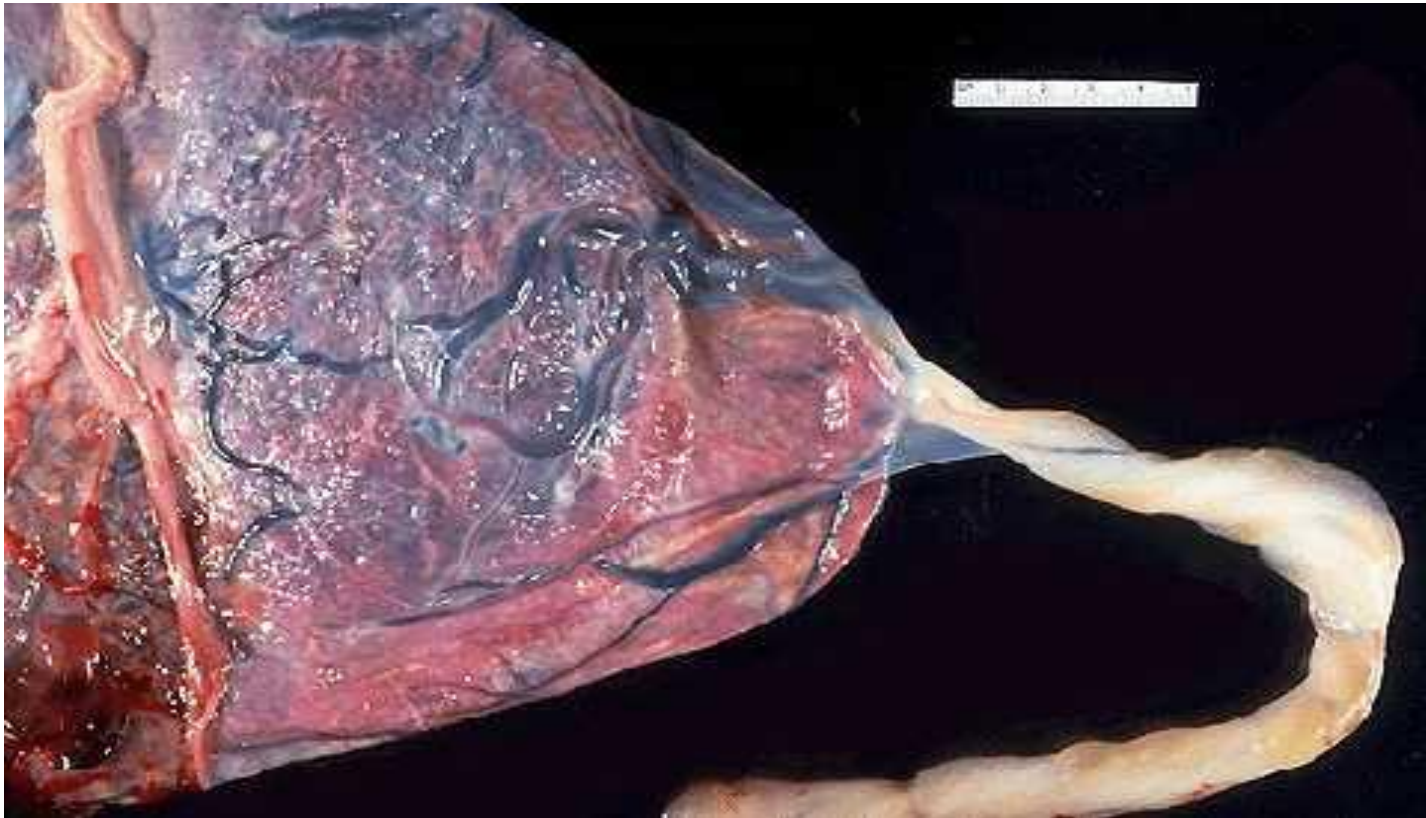

# Velamentous Insertion

- Normally, the veins of the baby run from the middle of the placenta via the umbilical cord to the baby.
- Velamentous insertion means that the veins traverse the membranes before they come together in the umbilical cord
- Incidence is about **1.1%** in singleton pregnancies and **8.7%** in twin gestations



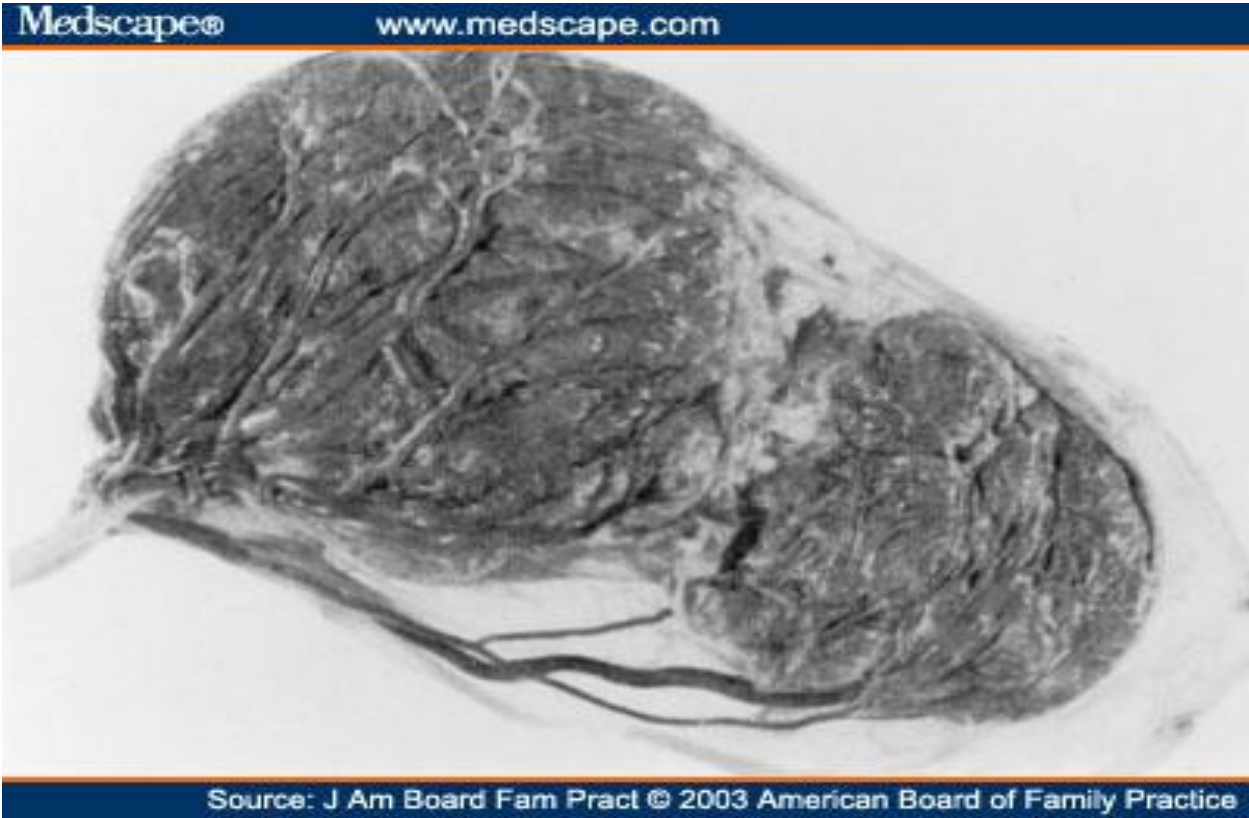
# Velamentous Insertion



Shirin Hasanpour

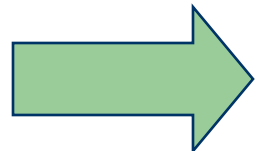


# Bi-lobed placenta with velamentous insertion

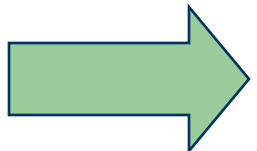
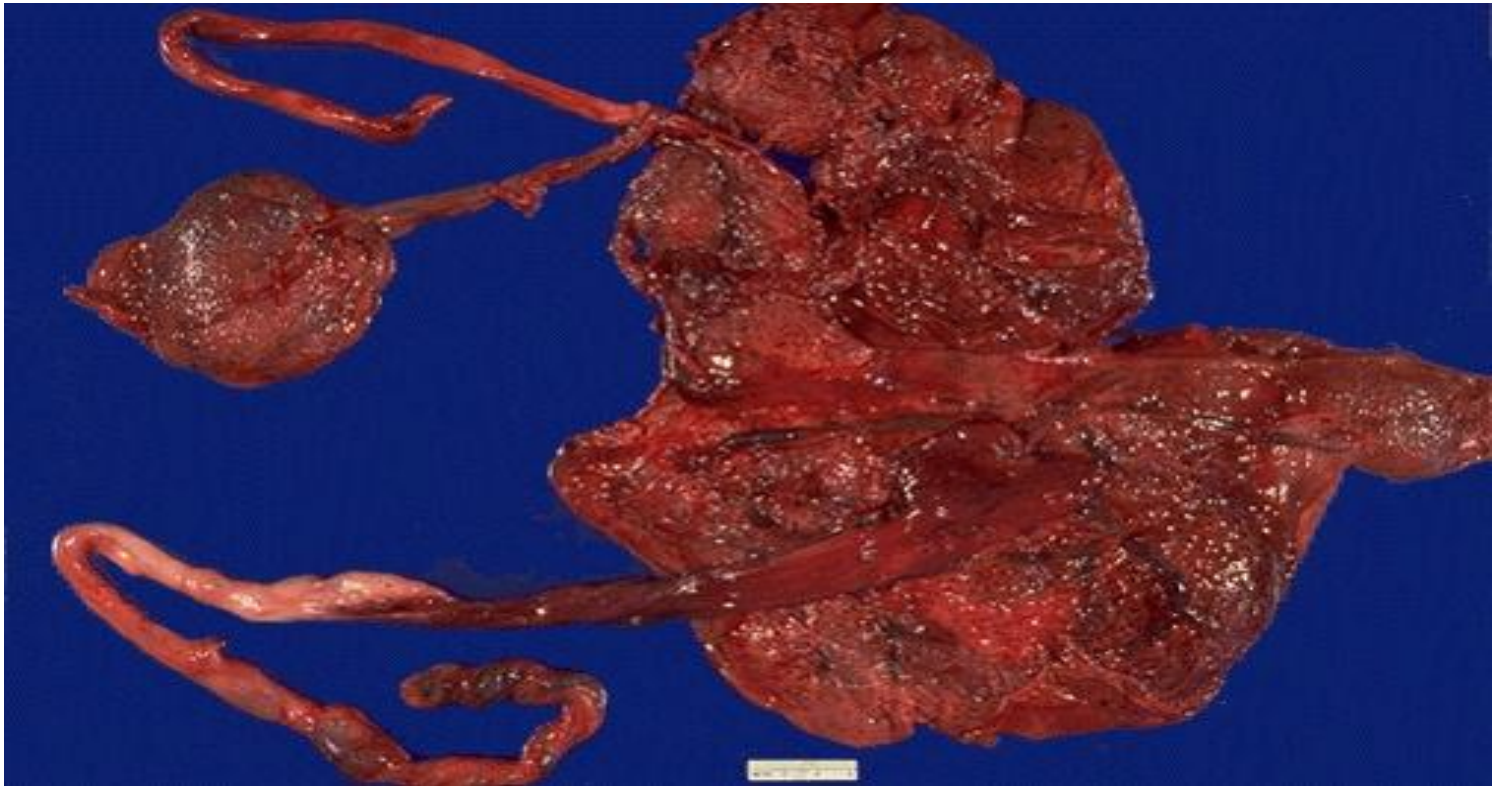


# Accessory (Succenturiate) Lobe

- The presence of a second or third placental lobe that is much **smaller** than the largest lobe
- Unlike bipartite lobes, these accessory lobes often show areas of **infarction or atrophy**
- The membranes between the lobes in such placenta can **be torn** during delivery, and the extra lobe may **be retained** resulting in postpartum bleeding



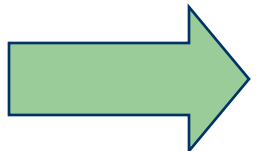
# Succenturiate Lobe





# Risk Factors for Vasa Previa

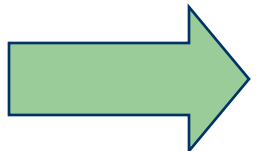
- **Bilobed and succenturiate placentas**
- **Velamentous insertion of the cord**
- **Low-lying placenta and/or placenta previa**
- **Multiple gestation**
- **Pregnancies resulting from in vitro fertilization**
- **Palpable vessel on vaginal exam**
- **Maternal history of uterine surgery**





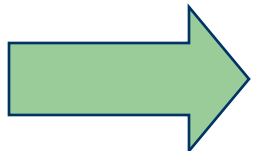
# Management

- When vasa previa **is detected** prior to labor, the baby has a much greater **chance of surviving**
- It can be detected during pregnancy with use of **transvaginal sonography**, preferably in combination with **color Doppler**
- Some researchers have suggested screening color Doppler in the second trimesters of patients with **risk factors** present on routine **20 week ultrasound**



# Management

- When vasa previa is diagnosed prior to labor, **elective caesarian delivery** can save the baby's life
- The International Vasa Previa Foundation recommends **hospitalization** in the third trimester, delivery **by 35 weeks**, and immediate **blood transfusion** of the infant in the event of a rupture (other researchers say C/S should occur **at 37-38 weeks**)



# Color Doppler of Vasa Previa

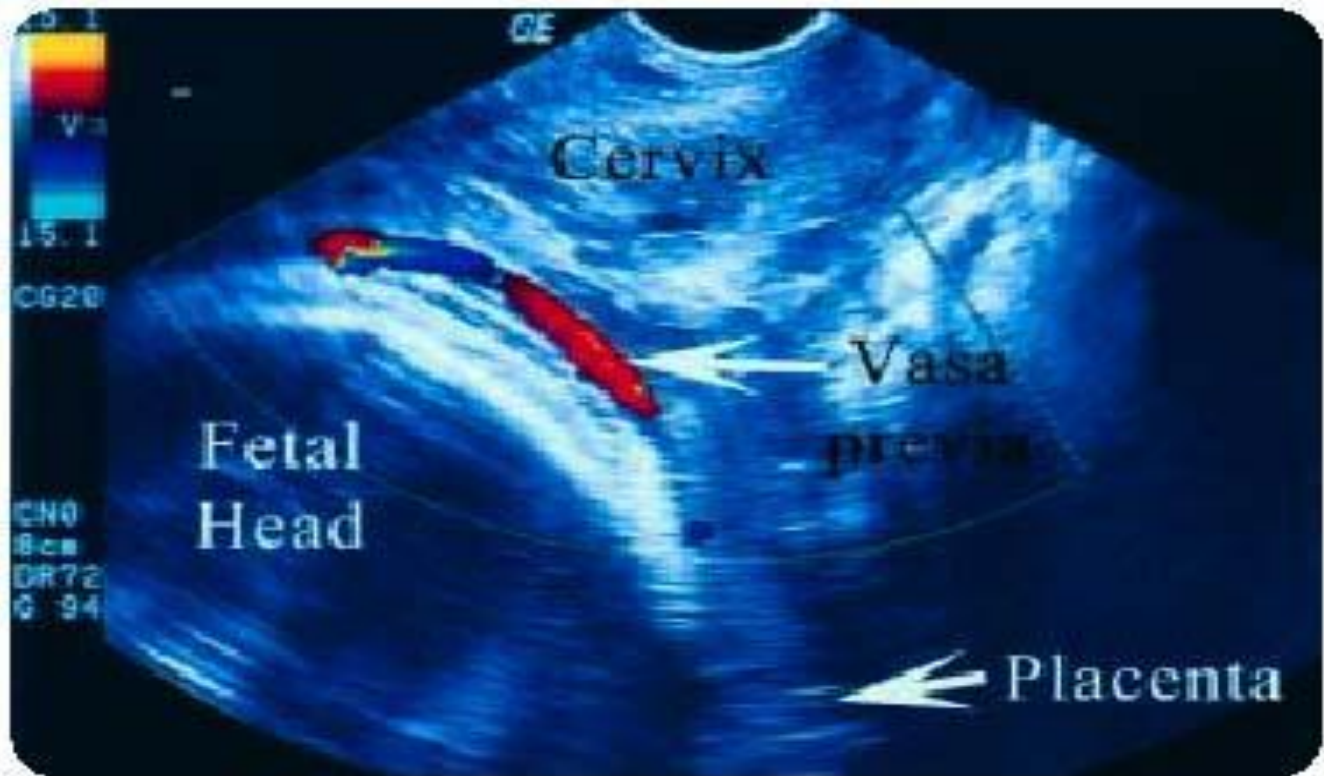
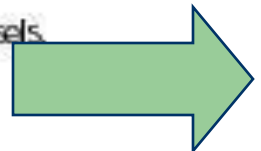
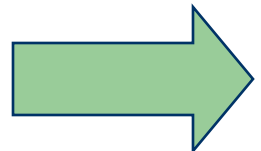


FIGURE 5. Color Doppler demonstrates flow through these structures, confirming that they are vessels.



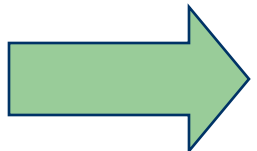
## “OK, I’ve made the diagnosis prenatally, now what?”

- **Hospitalize** the patient in the third trimester
- In the absence of bleeding, strict bed rest is not necessary, but reduced activity level should be encouraged(**RBR**)
- **Sexual activity** should be discouraged
- For patients less than 34 weeks, the administration of **steroids** should be considered to promote fetal lung maturation
- *And in our case of course, this is a High Risk Patient that needs to have **Obstetrician involvement***



## Making the Diagnosis in the Acute Setting

- **Clinical scenarios suggesting vasa previa:**
  - significant **bleeding** at the time of membrane rupture
  - sinusoidal** fetal heart tracing, esp. associated with vaginal bleeding
  - fetal heart rate abnormalities associated with vaginal bleeding
  - palpable vessels** on vaginal examination



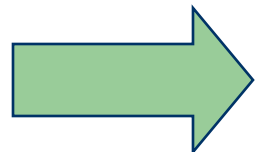
# What should I do if I suspect Vasa Previa during a delivery?

- The first step is to take all the information you have gathered and make a quick assessment:
  - 1) Did bleeding start with ROM?
  - 2) How does my fetal heart tracing look?
  - 3) Are there palpable vessels on vaginal exam?
- \*If there is some question to the diagnosis and the fetus appears stable on fetal heart tracing, one of the tests for fetal blood may be considered. But, according to ACOG this is not currently standard of care. You should not wait to do blood test if you have a high suspicion of vasa previa and the fetal tracing is non-reassuring.
- If assessment leads you to believe that vasa previa is possible, notify OB and Anesthesia immediately for possibility of emergent C/S.



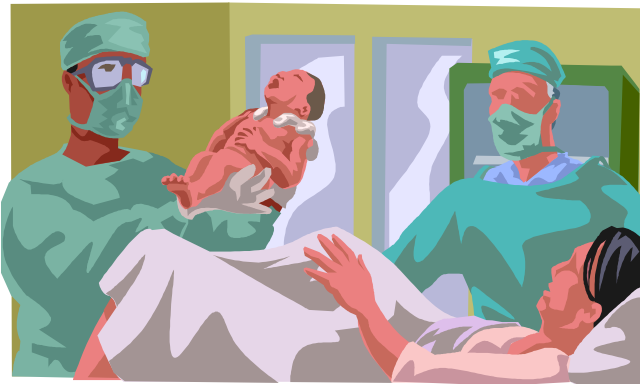# High Yield Fact about Vasa Previa

- A history of **abrupt onset** vaginal bleeding that **began with rupture of membranes** suggests vasa previa, especially when bleeding is accompanied by decreased fetal movement and a nonreassuring fetal tracing.

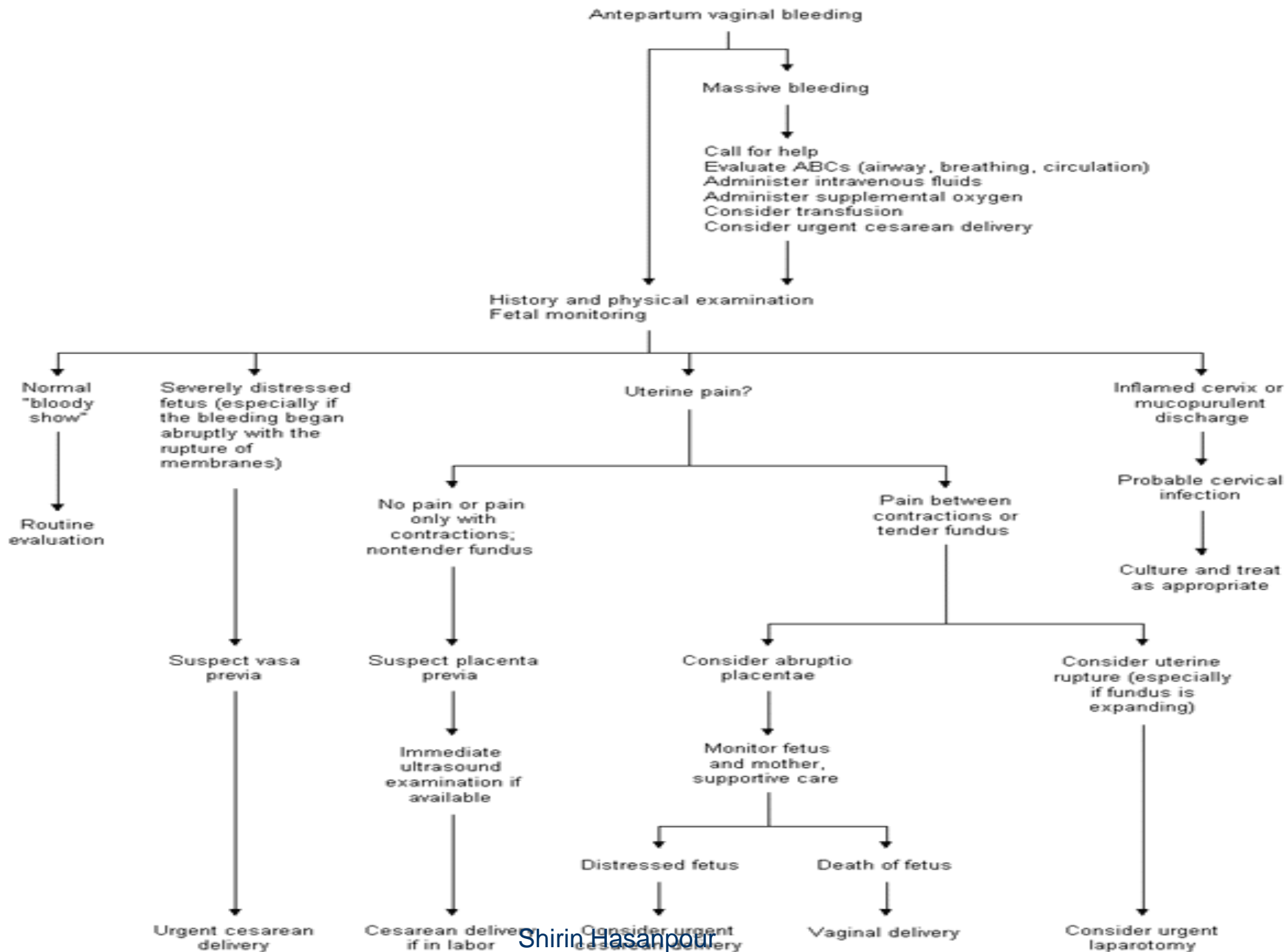


# Antepartum Hemorrhage

- A review algorithm to aid in the diagnosis and management of antepartum hemorrhage









Shirin Hasanpour